

## ADRENAL GANGLIONEUROMA IN AN ADULT - CASE REPORT

Joško Petričević<sup>1</sup>, Davor Librenjak<sup>2</sup>, Snježana Tomić<sup>3</sup>, Nikica Šutalo<sup>4</sup> & Ante Bošnjak<sup>4</sup>

<sup>1</sup>Department of Pathology, Cytology and Forensic medicine, University Clinical Hospital Mostar, Mostar, Bosnia and Herzegovina

<sup>2</sup>Department of Surgery, Clinical Hospital Center Split, Split, Croatia

<sup>3</sup>Department of Pathology, Forensic medicine and Cytology, Clinical Hospital Center Split, Split, Croatia

<sup>4</sup>Department of Surgery, University Clinical Hospital Mostar, Mostar, Bosnia and Herzegovina

\* \* \* \* \*

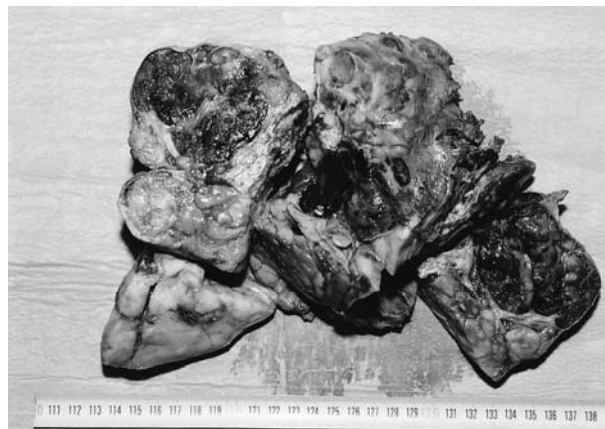### INTRODUCTION

Neuroblastic tumors arise from neural crest cells and encompass a spectrum from neuroblastoma – an undifferentiated, malignant tumor – to ganglioneuroma – a well – differentiated, benign neoplasm (Leavitt et al. 2000). Neuroblastomas and ganglioneuroblastomas represent the second most common group of solid extracranial neoplasms of infancy and childhood and account for approximately 8% of malignancies in these age groups. Most of these tumors are diagnosed by the age of 4, although rare examples have been reported in adults. Ganglioneuroblastoma is an intermediate type of tumor in the spectrum of ganglion cell tumors, containing both primitive neuroblastomatous and mature ganglioneuromatous elements of sympathetic cell origin (Shimada et al. 1999). Ganglioneuromas, ganglioneuroblastomas, and neuroblastomas are histologically differentiated by their stage of neuroblast maturation (Sovak et al. 2008). Ganglioneuromas are composed of mature ganglion cells and are considered benign tumors. Ganglioneuroblastomas and neuroblastomas are less mature and are considered more aggressive and dangerous (Lonergan et al. 2002).

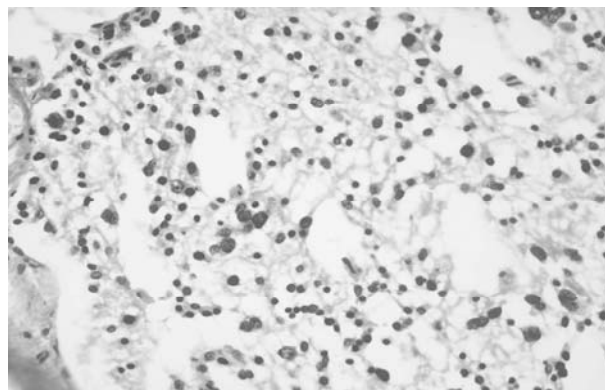
### CASE REPORT

A 48-year old man examined for progressive weakness in lower limbs and back pain on Department of Neurology. Computerized tomography (CT) observed a large, irregular mass retroperitoneal left. Mass was 25 – 20 – 15cm diameters. Right kidney and adrenal was normal. Multiple lymphadenopathies in paraaortic and aorta-caval lymph regions were observed. Patient had no clinical sign of endocrinal tumor and laboratory findings were negative for hormone-active tumor. Surgical exploration was made and adrenal tumor with ipsilateral kidney was removed. The lymph nodes in aorta-caval and paraaortic regions could not be removed. In pathologic examination; the left nephrectomy material was macroscopically 27 – 20 – 16 cm and inside it was seen compressed kidney measuring 11 – 7 – 3 cm and all around it is big tumoral mass measuring

20 – 19 cm (Figure 1). Tumor mass was well circumscribed and white in colour (like fish meat) and have areas of hemorrhage, necrosis and calcification. The histologic examination showed that the lesion was composed of large cells with abundant cytoplasm with large vesicular nuclei and prominent nucleolus, representing mature ganglion cells with no or minimal residual neuroblasts and background “schwannian stroma” comprised of organized fascicles of neurotic processes, mature Schwann cells, and fibroblasts (Figure 2).



**Figure 1.** Macroscopically, showing left nephrectomy material and inside it compressed kidney and all around it is big tumoral mass.



**Figure 2.** Microscopically, higher magnification x400, tumor is composed of large cells with abundant cytoplasm with large vesicular nuclei and prominent nucleolus

## DISCUSSION

Ganglioneuromas are rare, benign, fully differentiated tumors that contain mature Schwann cells, ganglion cells, fibrous tissue, and nerve fibers. These tumors have no immature elements (such as neuroblasts), atypia, mitotic figures, intermediate cells, or necrosis. The presence of any these tissue characteristics excludes the diagnosis of ganglioneuroma (Shin et al. 2002). Ganglioneuromas can grow almost anywhere along the paravertebral sympathetic ganglia, and they can sometimes grow in the adrenal medulla (Maweja et al. 2007). These tumors can arise de novo and result from the maturation of a ganglioneuroblastoma or neuroblastoma into a ganglioneuroma. They may also develop within a neuroblastoma treated with chemotherapy. Metastases from ganglioneuromas are exceedingly rare. Metastasis is thought to be the end result of matured ganglioneuroblastomas or neuroblastoma metastases rather than true ganglioneuroma metastases. Ganglioneuromas secrete catecholamines in as many as 37% of cases (Georger et al. 2001). Overall, patients with ganglioneuroma have a favorable prognosis. Ganglioneuromas are usually asymptomatic, regardless of their size, and they are typically discovered on a routine radiograph; however, abdominal pain, dyspnea, cough, and palpation of an abdominal mass may be clinical indicators of a ganglioneuroma. These tumors may be hormonally active, and hypertension, diarrhea, flushing, and virilization may occur as a result the secretion of catecholamine, vasoactive intestinal polypeptide, or androgenic hormone. Nonetheless, emergency situations caused by catecholamine secretion are rare (Patterson et al. 2009).

Treatment depends on surgical resection whenever possible, chemotherapy for tumors unlikely to be completely resected and radiotherapy for cases with regional nodal disease. Rousseau et al. 1999. reported a ganglioneuroblastoma of the left adrenal gland with liver metastasis. They had complete remission from combination therapy with chemotherapy and radiotherapy after surgical resection. Hiroshige et al. 1995 presented a case of well-differentiated ganglioneuroblastoma treated with surgical resection.

## CONCLUSION

Surgical resection is sufficient for low risk and non-metastatic tumors. Combination therapy with chemotherapy and radiotherapy is necessary for disseminated cases.

**Acknowledgements:** None.

**Conflict of interest :** None to declare.

## References

1. Georger B, Hero B, Harms D, Grebe J, Scheidhauer K & Berthold F: *Metabolic activity and clinical features of primary ganglioneuromas. Cancer* 2001; 91:1905-13.
2. Hiroshige K, Sanode S, Fujite M, Takasugi M, Kuroiwa A & Inatomi H: *Primary adrenal ganglioneuroblastoma in an adult. Intern Med* 1995; 34:1168-73.
3. Leavitt JR, Harold DL & Robinson RB: *Adrenal ganglioneuroma: A familial case. Urology* 2000; 56: 508.
4. Lonergan GJ, Schwab CM, Suarez ES & Carlson CL: *Neuroblastoma, ganglioneuroblastoma, and ganglioneuroma: radiologic-pathologic correlation. Radiographics* 2002; 22:911-34.
5. Maweja S, Materne R, Detrembleur N, de Leval L, Defechereux T, Meurisse M: *Adrenal ganglioneuroma. Am J Surg* 2007; 194:683-4.
6. Patterson AR, Barker CS, Loukota RA & Spencer J: *Ganglioneuroma of the mandible resulting from metastasis of neuroblastoma. Int J Oral Maxillofac Surg* 2009; 38:196-8.
7. Rousseau P, Bernard A, Favre JP, Arnould L, Cheynel N & Manuelian M: *Ganglioneuroblastoma in the adult. Presse med* 1998; 27:1677-79.
8. Shimada H, Ambros IM, Dehner LP, Hata J, Joshi VV & Roald B: *Terminology and morphologic criteria of neuroblastic tumors: recommendations by the International Neuroblastoma Pathology Committee. Cancer* 1999; 86:349-63.
9. Shin JH, Lee HK, Khang SK, Kim DW, Jeong AK, Ahn KJ et al.: *Neuronal tumors of the central nervous system: radiologic findings and pathologic correlation. Radiographics* 2002; 22:1177-89.
10. Sovak MA, Aisner SC & Aisner J: *Tumors of the Pleura and Mediastinum. In Abeloff MD, Armitage JO, Niederhuber JE, Kastan MB & McKenna WG (eds): Abeloff's Clinical Oncology, chap 77, Churchill Livingstone Elsevier, 2008.*

### Correspondence:

Joško Petričević, MD, PhD

Department of Pathology, Cytology and Forensic medicine, University Clinical Hospital Mostar

Kralja Tvrtka bb, 88 000 Mostar, Bosnia and Herzegovina

E-mail: josko.petricevic@yahoo.com